

The Role of Methotrexate Chemotherapy in Impeding Rupture - Low-Risk Gestational Trophoblastic Neoplasia Management: A Case Report

Betari Dhira Paramita, Sutrisno, Akhmad Yogi Pramartira

Department of Obstetric dan Gynecology, Faculty of Medicine, Padjadjaran University, Bandung Indonesia – Prof. Dr. Margono Soekarjo General Hospital

Correspondence: Betari Dhira Paramita, Email: betaridhira@gmail.com

Abstract

Background: Gestational Trophoblastic Neoplasia (GTN) is a type of malignant growth that originates from abnormal proliferation of placental trophoblast. GTN can even be cured in its metastatic forms with a high success rate of 90-100%. However, estimating the incidence of Gestational Trophoblastic Disease (GTD) in Indonesia is challenging due to underreporting and lack of recognition. GTD can be classified into two types: hydatidiform mole and GTN. Low-risk GTN is currently treated with methotrexate.

Case presentation: A 24-year-old woman experienced vaginal bleeding for three weeks after her molar evacuation. Upon admission to Prof. Dr. Margono Soekarjo (RSMS) General Hospital, the patient was in grade III hypovolemic shock. Post-molar evacuation β -hCG examination showed increasing periodic, while ultrasound examination revealed thinning of the myometrium with vesicular pattern invaded at the fundus. Transvaginal examination results showed bilateral lutein cysts. The patient was diagnosed with low-risk GTN (FIGO score 6) with impending uterine rupture and bilateral non-papillary multilocular ovarian cysts.

Discussion: GTN during pregnancy requires accurate diagnosis and prompt treatment. GTN patients who reach an undetectable β -hCG level are at risk of perforation, infection, and higher uterine bleeding. MTX chemotherapy has been proven effective as the main therapy for low-risk GTN, and the β -hCG level can be relied upon as an indicator of treatment response. The MTX chemotherapy provides a favorable prognosis for reducing β -hCG levels to prevent uterine rupture.

Conclusions: The administration of MTX chemotherapy successfully prevents rupture by reducing the β -hCG levels, followed by three cycles of consolidation therapy to prevent recurrence.

Key words: Gestational Trophoblastic Neoplasia (GTN), Placental Trophoblast, Methotrexate, Uterine Rupture.

Peran Kemoterapi Metotrexat pada Tatalaksana Tumor Trofoblastik Gestasional Risiko Rendah dengan Ancaman Ruptur Uteri: Laporan Kasus

Abstrak

Latar belakang: Neoplasia Trofoblas Gestasional (GTN) merujuk pada lesi ganas yang timbul dari proliferasi trofoblas plasenta yang abnormal. Meskipun dalam bentuk metastasis, GTN dapat disembuhkan dengan tingkat kesembuhan mencapai 90 – 100%. Di Indonesia, estimasi insiden GTD (Penyakit Trofoblas Gestasional) menjadi tantangan terutama karena tidak semua kasus dilaporkan atau dikenali. GTD terbagi menjadi mola hidatidosa dan neoplasia trofoblas gestasional (GTN). Saat ini, metotreksat direkomendasikan untuk GTN dengan risiko rendah.

Presentasi Kasus: Seorang wanita berusia 24 tahun mengalami perdarahan vagina selama 3 minggu setelah evakuasi molanya. Saat masuk ke Rumah Sakit Umum Prof. Dr. Margono Soekarjo (RSMS), pasien dalam keadaan syok hipovolemik stadium III. Pemeriksaan β -hCG pascaevakuasi mola menunjukkan peningkatan periodik dan pemeriksaan ultrasonografi menunjukkan penipisan miometrium dengan pola vesikular yang menginvasi fundus. Hasil pemeriksaan transvaginal menunjukkan adanya kista lutein bilateral. Pasien didiagnosis dengan GTN risiko rendah (skor FIGO 6) dengan ancaman ruptur uterus dan kista ovarium multilokular bilateral non-papiler.

Pembahasan: GTN selama kehamilan membutuhkan diagnosis yang akurat dan pengobatan yang cepat. Kemoterapi metotreksat merupakan terapi utama untuk GTN dengan risiko rendah, dan tingkat β -hCG dapat digunakan sebagai indikator respons terhadap pengobatan. Pasien GTN yang mencapai tingkat β -hCG yang tidak terdeteksi berisiko mengalami perforasi, infeksi, dan perdarahan rahim yang lebih tinggi. Penggunaan metotreksat (MTX) sebagai pengobatan utama untuk GTN dengan risiko rendah telah terbukti efektif dan memberikan prognosis yang menguntungkan.

Kesimpulan: Pemberian kemoterapi MTX berhasil mencegah terjadinya ruptur karena kadar β -hCG menurun dan dilanjutkan terapi konsolidasi 3 siklus untuk mencegah terjadinya rekurensi.

Kata kunci: Gestational Trophoblastic Neoplasia (GTN), Plasenta Trofoblas, Methotrexate Ruptur Uteri.

Introduction

Low-risk gestational trophoblastic neoplasia (GTN), defined by FIGO/WHO scores of 0-6, is associated with a high curability rate, approximately 100% survival rate. GTN is a rare type of cancer that occurs in placental tissue and is caused by abnormal fertilization resulting from abnormal fertilization. Hydatidiform mole (HM) is one type of GTD (Gestational Trophoblastic Disease) that can progress to GTN. GTN can be diagnosed through staging evaluation using clinical, laboratory, and radiological resources in accordance with FIGO 2002 recommendations. After GTN diagnosis is established, patients are classified based on FIGO 2002 criteria of low-risk group (≤ 6) or high-risk group (≥ 7).¹

Most patients with GTN after molar pregnancy can be detected through β -hCG monitoring thus extensive investigations are rarely needed. The minimum requirements for evaluating post-molar GTN are illustrated in Figure 1.² The classification system for GTN has been controversial for many years, as there is no consensus on the optimal classification system worldwide.³ The World Health Organization (WHO) adopted the Bagshawe classification system in 1982, which was later simplified by the ISSTD in 2000 by combining the FIGO anatomical classification system; the WHO clinical classification system was classified into low-risk (0-6) and high-risk (7) groups.^{4,5} This score aims to predict the potential development of resistance to methotrexate (MTX) or actinomycin-D chemotherapy.

The combined and revised FIGO and WHO prognostic scoring system (2000) was endorsed by FIGO in 2002 (Table 1) and has been recommended for use.⁶⁻⁷

Currently, there is still a controversy about this risk score, especially whether low-risk patients with scores of 5-6 should still be considered low-risk and treated with single-agent chemotherapy.⁸⁻¹¹ There are concerns that these patients are more likely to develop resistance to single-agent chemotherapy. Although this scoring system has been used for a long time, there still need to be prospective validation studies to evaluate its accuracy.^{3,12}

Methotrexate (MTX) is a chemotherapy drug used to treat low-risk GTN. GTN is a malignant transformation after a complete or partial hydatidiform mole. The diagnosis of GTN is made by evaluating β -hCG levels, and treatment is recommended when there is a plateau or increase in β -hCG levels. MTX can also be used to treat heavy vaginal bleeding, choriocarcinoma, metastatic spread, and radiological opacities larger than 2 cm on a chest radiograph. If serum β -hCG levels are more than 20,000 for more than four weeks after evacuation, MTX can be administered as a treatment. The use of MTX in treating GTN has been proven to be highly effective and provides a good prognosis, especially for low-risk GTN.¹³

Three-quarters of women with low-risk GTN can fully recover after receiving first-line treatment. In Europe and North America, MTX is more commonly used as the first-line treatment than actinomycin-D.¹⁴ Generally, MTX is usually safe to use, but it can cause

Table 1 β -hCG Levels During Period and Choriocarcinoma Diagnosis

The plateau of β -hCG levels lasts for four measurements over a period of three weeks or more (days 1, 7, 14, and 21).

The increase in β -hCG levels occurs during three consecutive weekly measurements over a period of two weeks or more (days 1, 7, and 14).

The β -hCG levels remain elevated for ≥ 6 months.

Histological diagnosis of choriocarcinoma.

Figure 1 The Recommended Staging Assessment for Gestational Trophoblastic Neoplasia Post-Molar.

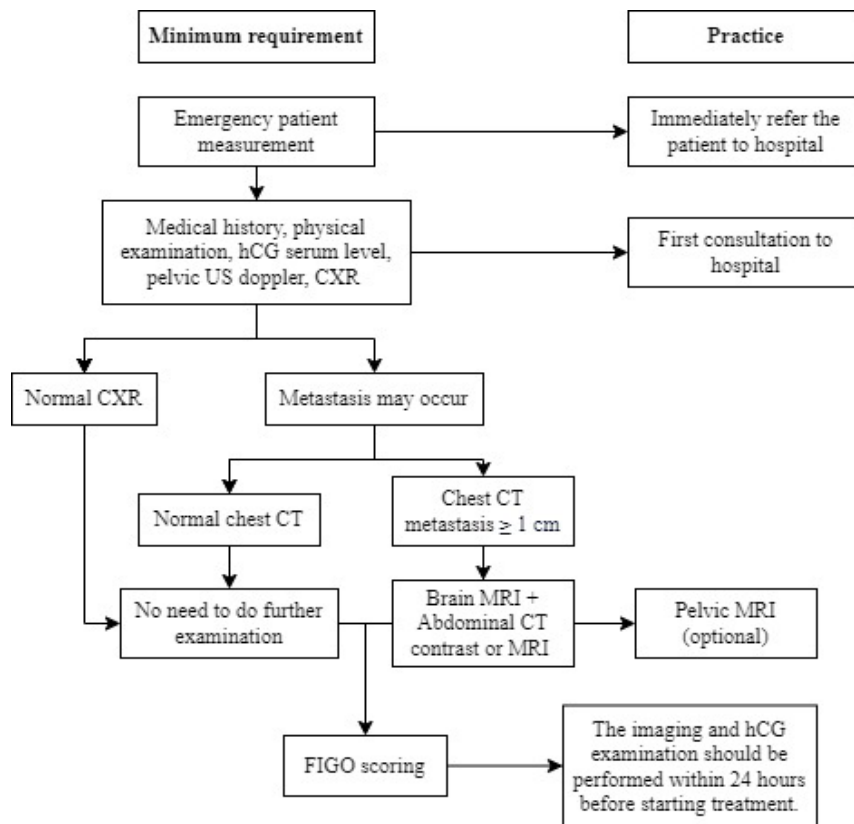


Table 2 The International Federation of Gynecology and Obstetrics (2000) Scoring System for Gestational Trophoblastic Neoplasia Based on Prognostic Factors.

	0	1	2	4
Age (years)	<40	≥40	-	-
Antecedent pregnancy	Mole	Abortion	Term	-
Interval from end of index pregnancy to diagnosis of GTN (months)	<4	4 – 6	7 – 12	>1
Pre-treatment serum hCG (IU/L)	10 ³	10 ³ – 10 ⁴	10 ⁴ – 10 ⁵	>10 ⁵
Number of metastases	0	1 – 4	5 – 8	>8
Site of metastases	Lung	Spleen, kidney	Gastrointestinal	Liver, brain
Largest tumor size (cm)	< 3	3 – 5	5	
Previous failed chemotherapy	-	-	Single drug	Two or more drugs

Patient scores are calculated from individual scores for eight prognostic categories.

side effects such as mucositis and eye pain; and in rare cases, it can lead to chemical serositis, causing pleuritic and peritoneal pain.¹⁵

The MTX-FA regimen for eight days appears to have a lower incidence of mucositis compared to the more commonly used 5-day MTX regimen in North America.¹⁶ The incidence rate of side effects requiring a change in treatment approach due to low toxicity ranges from 1 to 6% with the use of both the MTX-FA 8-day regimen and the 5-day MTX regimen. In a recent non-randomized comparison between the MTX-FA 8-day regimen and pulse actinomycin-D in 131 low-risk GTN patients treated in Brazil, side effects with increased gastrointestinal effects occurred more frequently in patients receiving pulse actinomycin-D.¹

Case Report

A 24-year-old mother is a referral patient from Dadi Keluarga Hospital, Ciamis, with complaints of post-evacuation bleeding from

the birth canal admitted for three weeks. However, the patient experienced increased bleeding one week before admission to the hospital. The bleeding wetted four to five pads per day, accompanied with the passage of tissue resembling fish eggs or bubbles.

The patient arrived in a state of hypovolemic shock with a blood pressure of 64/52 mmHg (stage III hypovolemic shock) and a heart rate of 120 beats per minute. The patient received treatment at Dadi Keluarga Hospital with a diagnosis of hydatidiform mole on February 16, 2023, and underwent regular β -hCG evaluation examinations.

The patient underwent inpatient treatment for three days at Margono Hospital for general condition improvement, after which the patient was discharged and underwent weekly β -hCG evaluation. In the 4-week periodic examination, β -hCG results showed a plateau and increase (week 1: 4433, week 2: 4743, week 3: 3819, and week 4: 8342). Upon examination, a uterine mass measuring 10.71x6.06 cm appeared as a solid mass with cystic parts measuring 3.88x3.75x3.70 cm.

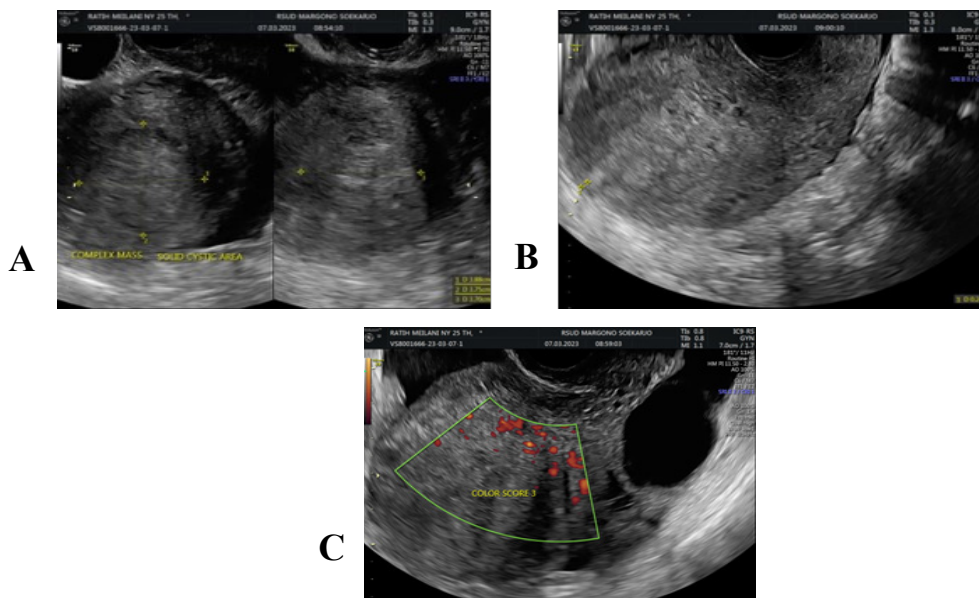


Figure 1 The results of transvaginal ultrasonography examination for patient A. A solid mass with cystic parts measuring 3.88x3.75x3.70 cm is indicated (A). The myometrial thickness at the fundus is 0.24 cm (B). Vascularization is seen in the solid part, with a color score of 3 (C).

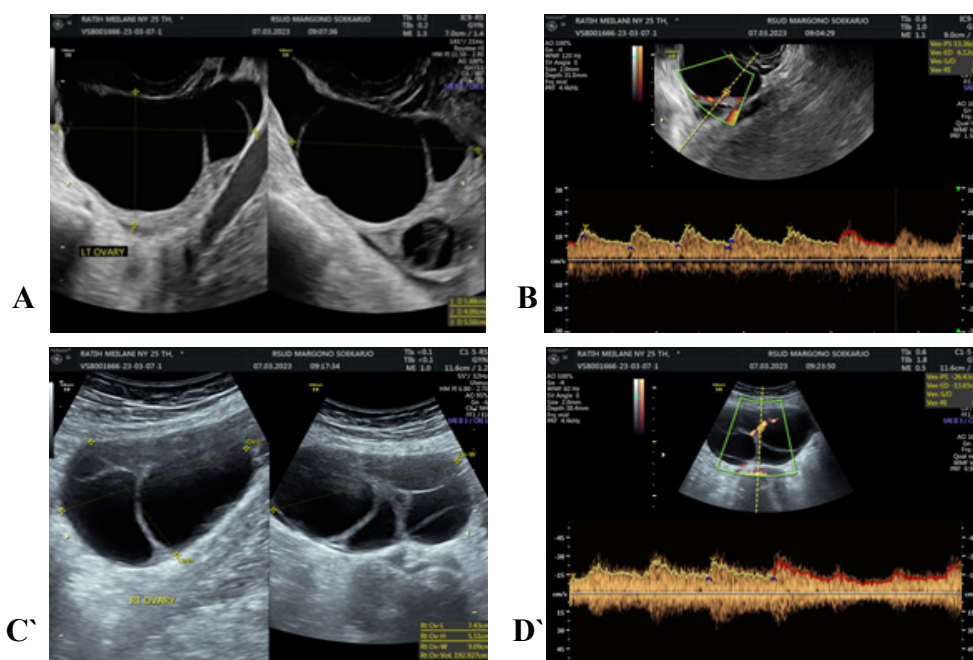


Figure 2 The results of Transvaginal Ultrasonography Examination for Patient A. A multilocular cystic mass is seen in the right ovary with dimensions of 7.43x5.51x9.09 cm (A). Doppler imaging of the right ovarian artery shows a RI of 0.48 (B). In the left ovary, a multilocular cystic mass is observed with dimensions of 5.85x4.00x5.50 cm (C). Doppler imaging of the left ovarian artery shows an RI of 0.54 (D).

The myometrial thickness at the fundus was 0.24 cm, with a color score of 3.

Upon transvaginal examination, a multilocular cystic mass was found in the right ovary with dimensions of 7.43x5.51x9.09 cm, thin septum, without solid components, no acoustic shadow appearance, with a right ovarian artery Doppler RI of 0.48. In the left ovary, a multilocular cystic mass was observed with dimensions of 5.85x4.00x5.50 cm, a thin septum without solid components, no acoustic shadow appearance, and a left ovarian artery Doppler RI of 0.54.

In this case, thinning of the myometrium at the fundus with a thickness of 0.24 cm was found, and post-curettage β -hCG levels showed a plateau and increase. Based on scoring using the International Federation of Gynecology and Obstetrics (2000), this patient is diagnosed with impending uterine rupture in gestational trophoblastic neoplasia stage I FIGO score 6 (Low Risk); bilateral

non-papillary multilocular ovarian cysts.

Discussions

Invasive mole is one of the major clinicopathological forms of GTN. Invasive mole, also known as malignant hydatidiform mole, has metastatic and myometrial invasion properties. Approximately 10-15% of complete moles and 0.5% of partial moles progress to invasive moles.² If this condition is not diagnosed and treated properly, it is likely to become one of the leading causes of increased maternal mortality in Indonesia. In this case, a 24-year-old woman was diagnosed with impending uterine rupture in gestational trophoblastic neoplasia stage I FIGO score 6 (Low Risk); bilateral non-papillary multilocular ovarian cysts. The diagnosis was made through history taking, physical examination, laboratory tests, and ultrasonography (USG). Laboratory tests

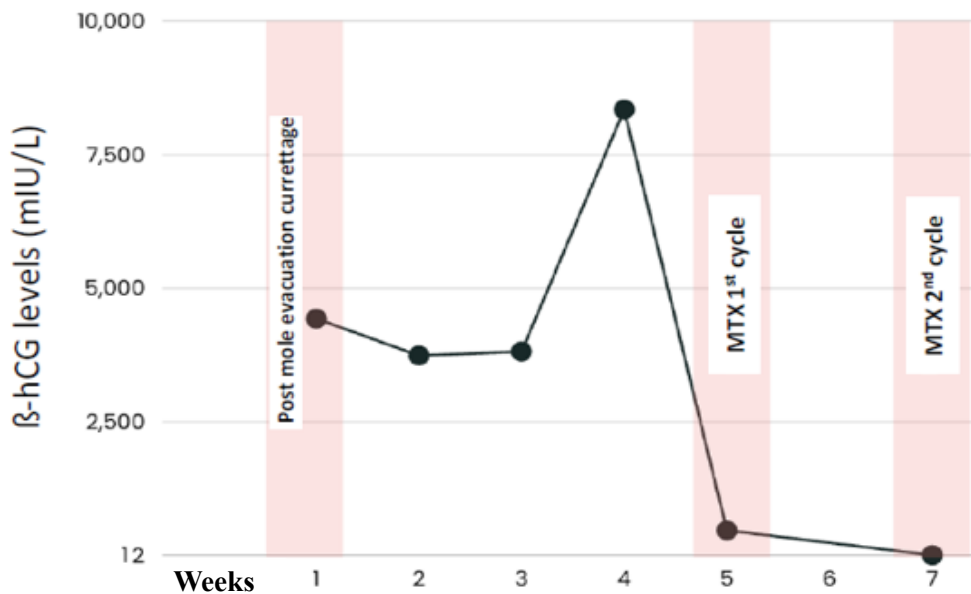


Figure 3 The β-hCG Level Curve in the Patient.

included measuring β-hCG levels, which are the gold standard for GTN.²⁶

After undergoing curettage at Dadi Keluarga Hospital, the patient’s β-hCG levels were monitored. After monitoring for four weeks referring to the β-hCG regression curve, the β-hCG levels remained high, as shown in Figure 3. β-hCG can be used to diagnose gestational trophoblastic disease post-hydatidiform mole that progresses to malignancy, specifically when β-hCG levels remain stable for four consecutive measurements over three weeks or more, on days 1, 7, 14, and 21. The histological diagnosis of choriocarcinoma can be established if β-hCG levels increase for six months or more after therapy.²⁴⁻²⁵ Chemotherapy is the first-line treatment recommended for sensitive invasive mole or low-risk patients. To determine the risk category in patients, we use the WHO Prognostic Index Score Assessment. In this case, the patient with score of 6 in the FIGO assessment system was placed in the low-risk category (within the range of 0-6) and likely to be sensitive to chemotherapy agents. Repeated dilation and curettage are strongly not recommended as they can pose a high risk of complications such

as uterine perforation, bleeding, infection, and anesthesia-related complications. High-risk GTN cases should be treated with combination chemotherapy with or without adjuvant surgery and radiotherapy.²⁰ Previous studies have described the use of different doses of methotrexate (MTX) (Table 2) in various countries for the treatment of low-risk gestational trophoblastic neoplasia (GTN). The MTX-FA regimen for eight days is the standard first-line treatment in the UK and is well-tolerated, with the first two injections given in the hospital to monitor for possible bleeding. The MTX 5-day regimen is preferred in North America; however, this dose is associated with a higher incidence of mucositis. This study used a dose of MTX 50 mg and leucovorin 12.5 mg for five days. Subsequently, the patients underwent β-hCG level measurement after chemotherapy and ultrasound evaluation.²¹⁻²³ In this case, the β-hCG level decreased by 95% after post-MTX chemotherapy from its previous value, as shown in Figure 3. Since the β-hCG level was still 472.4 mIU/L, the patient underwent a second cycle of MTX therapy and was evaluated by ultrasound before the second cycle of chemotherapy.

Table 3 The MTX Dose in Low-Risk GTN Cases.

Methotrexate regimen	Dosage and Schedule	Primary responses (%)
Methotrexate folinic acid 8-day regimen (MTX-FA 8 days)	50 mg of intramuscular MTX on days 1, 3, 5, 7 with folinic acid assistance 24-30 hours after MTX on days 2, 4, 6, 8 every 2 weeks. The modified Bagshawe regimen also includes 1 mg/kg of MTX followed by 10 mg of folinic acid on days 2, 4, 6, 8.	57 – 90
Methotrexate 5-days regimen (MTX 5 days)	0.4 mg/kg (maximum 25 mg) intravenously or intramuscularly for five days every two weeks.	81 – 89
Low-dose methotrexate	30-50 mg/m ² of intramuscular MTX, repeated every week.	60 – 81
High-dose methotrexate	100 mg/m ² intravenous injection followed by IV infusion of 200 mg/m ² over 12 hours with folinic acid rescue, repeated every two weeks.	65 – 92

A previous case report discussed invasive mole, which can lead to uterine rupture in patients with GTN. The case report presented a 31-year-old patient who underwent curettage due to abortion and complained of post-curettage bleeding for 53 days. Laboratory tests and an abdominal CT scan revealed very high levels of β -hCG in the patient and a mass in the myometrium with invasion into the pelvic wall. When chemotherapy treatment was planned, the patient was found in shock and assessed for tenderness, muscular defense in the entire abdominal area, without vaginal bleeding. Consequently, the decision was made to perform exploratory laparotomy, and a rupture of 8 cm was found.²⁵ In cases of GTN, patients should be monitored for signs of uterine rupture; uterine perforation is a serious issue that requires emergency surgical management with consideration for uterine removal. This case report emphasizes the importance of monitoring symptoms, β -hCG levels, and imaging results to detect signs of uterine rupture in GTN patients.

Based on previous research, during MTX (methotrexate) administration for the treatment of low-risk gestational trophoblastic

neoplasia (GTN), it needs to monitor potential side effects, such as mucositis, red eyes, and serositis, where serositis is a rare side effect of MTX that can lead to pleuritic and peritoneal pain. In addition, patients receiving MTX should be monitored for bleeding. Previous studies using the MTX-FA regimen for eight days have shown a lower incidence of mucositis in research subjects compared to those given the MTX regimen for five days.¹ In this case, on the first day of MTX administration, the patient complained of passing bubble-like structures resembling fish eggs along with blood clots wetting two pads, without abdominal pain or muscular defense. We concluded that the patient did not experience uterine rupture. Monitoring signs of uterine rupture, in this case, is important because the ultrasound examination showed a myometrial thickness at the fundus of 0.24 cm. A transvaginal ultrasound examination is performed to evaluate the condition of the reproductive organs after the first cycle of MTX chemotherapy. The results showed a retroflexed uterus, homogeneous myometrial echoparenchyma with dimensions of 6.89×5.78×4.84 cm, and a volume of 100.92 cm³. In the uterine cavity, a hypoechoic solid mass was observed with indistinct

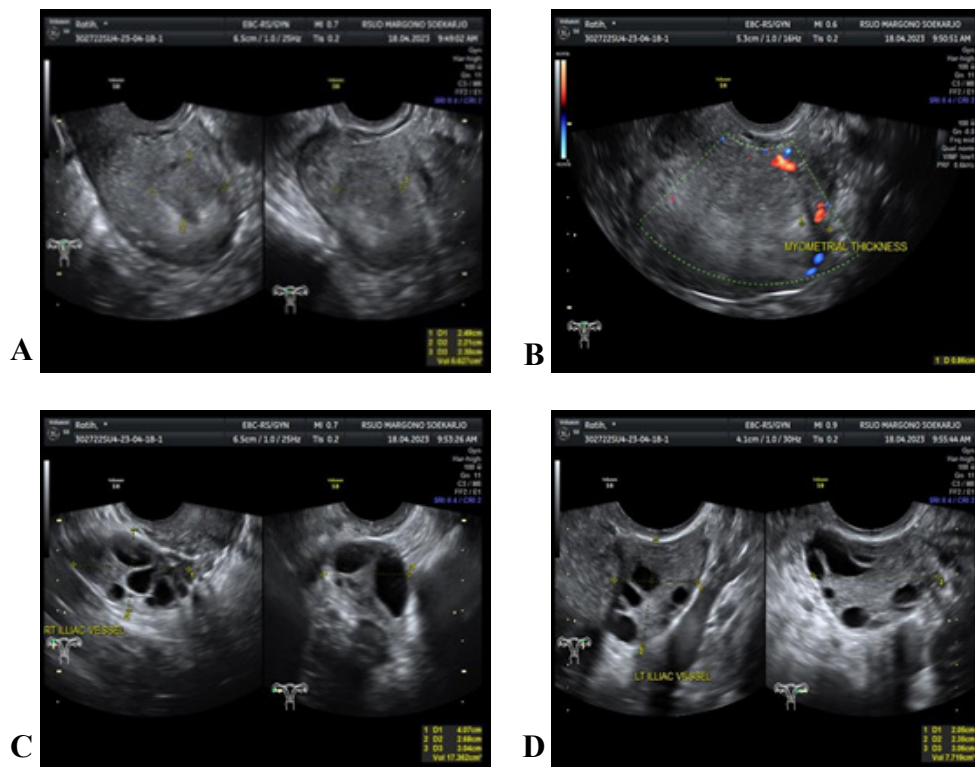


Figure 4 The results of transvaginal ultrasonography examination in the patient after evaluating the first cycle of MTX chemotherapy. The uterine cavity appears with a hypoechoic solid mass, indistinct borders, irregular edges, invasive into the myometrium, measuring 2.49x2.21x2.30 cm, with a volume of 6,027 cm³ (A). Doppler imaging shows a color score of 2, with myometrial thickness of 0.86 cm (B). The right ovary is normal in shape and size, measuring 4.07×2.68×3.04 cm, with a volume of 17.362 cm³ (C). The left ovary is normal in shape and size, measuring 2.05x2.35×3.06 cm, with a volume of 7.719 cm³ (D).

borders, irregular edges, invasive into the myometrium, measuring 2.49x2.21x2.30 cm, with a volume of 6,027 cm³, and a color score of 2, with myometrial thickness of 0.86 cm. The right and left ovaries were normal in shape and size. In addition, no bilateral pelvic lymphadenopathy was detected.

Based on transvaginal ultrasound evaluation, the mass in the uterine cavity has reduced in size, and no uterine rupture was found, with a myometrial thickness of 0.86 cm. Examination of the right and left ovaries revealed significant changes in size, as seen on ultrasound with a decrease in size. In GTN cases, ovarian enlargement is often observed due to ovarian theca lutein cysts. Theca lutein ovarian cysts develop in the ovaries

and contain brownish or serosanguineous fluid, typically bilateral and multilocular. The formation of these cysts may be associated with increased levels of β -hCG and prolactin in the blood. Theca lutein ovarian cysts typically develop in patients with very high β -hCG levels. Because the uterus can also enlarge significantly, theca lutein cysts may be difficult to palpate, but ultrasound can estimate their presence and size. After molar evacuation, theca lutein cysts usually regress spontaneously within two to four months.²⁶ Initially, post-molar evacuation ultrasound examination revealed multilocular cystic masses ≥ 7 cm in size in both ovaries. However, on subsequent ultrasound evaluations, both ovaries showed normal shape and size due to

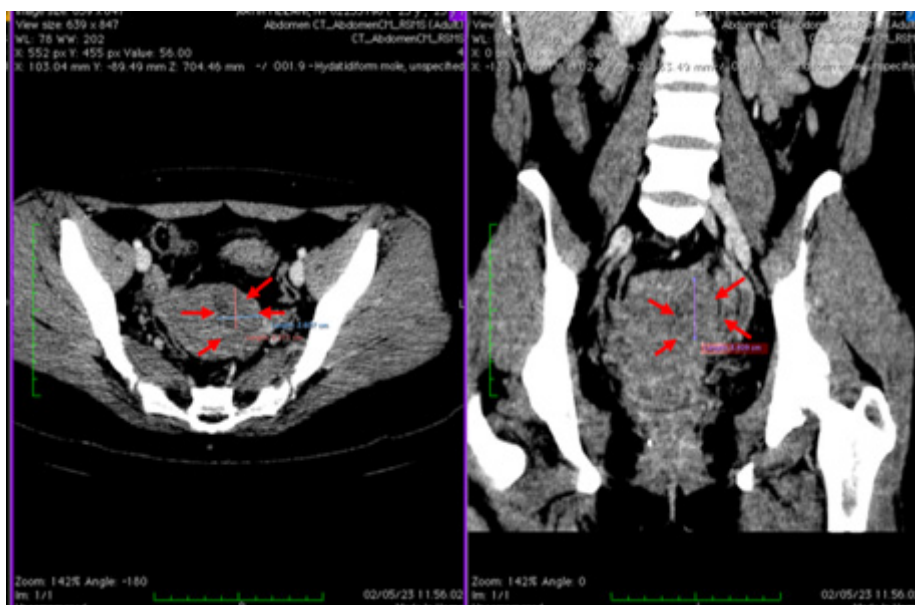


Figure 5 The evaluation result of the CT scan of the abdomen with contrast shows a solid hypodense mass in the uterine cavity measuring 2.6x2.3x3.4 cm with unclear borders and irregular edges.

the MTX chemotherapy reducing the β -hCG levels in the patient by 95% from the initial post-molar evacuation levels, as these cysts are correlated with β -hCG levels.

The β -hCG level can be used as a reliable marker to monitor treatment response in GTD patients. In effective chemotherapy treatment, the β -hCG level can decrease rapidly to reach a low but not undetectable level. After treatment, patients should undergo regular monitoring of the β -hCG level until it reaches its lowest level for at least 24 consecutive months. This is important to ensure recovery and prevent disease recurrence.²⁶

In this case, after the second chemotherapy, the β -hCG result was 12.49, and then the patient was scheduled for the third chemotherapy until the β -hCG level became undetectable.²⁶ After achieving the target β -hCG level, further management includes consolidation therapy with two or more cycles of MTX aimed at preventing relapse. A study suggests that three consolidation cycles may be better than two to reduce the risk of relapse with the same medication.²⁷ Previous research in the United

Kingdom showed that consolidation therapy was administered for six weeks (three cycles of MTX chemotherapy), with a relapse rate of 4.0% compared to consolidation, with two cycles having a relapse risk of 8.3%.²⁷

However, before patients undergo consolidation, those with GTD should undergo imaging after reaching the target β -hCG. This is done to assess treatment success and identify possible recurrence or metastasis. Imaging typically includes chest CT scans, abdominal and pelvic ultrasound or CT scans, and head MRI if necessary.²⁶ The patient underwent an evaluation CT scan with contrast of the abdomen, and a mass in the uterine cavity was found to have reduced in size compared to the initial findings when the patient was first referred.

It is important to note that GTD patients who achieve undetectable levels of β -hCG have a potential risk of perforation, infection, and higher uterine bleeding, especially if they plan to use an IUD. However, patients still need to undergo strict monitoring and use effective contraception during the follow-up period of gonadotropin therapy aimed at

preventing pregnancy during treatment and evaluation periods.²⁶

Conclusion

GTD can occur during pregnancy. This condition requires accurate antenatal diagnosis and treatment to prevent serious complications and recurrent miscarriages. Chemotherapy is the main therapy for low-risk GTN. Most cases are sensitive to chemotherapy, and β -hCG levels can reliably indicate the response to treatment. However, GTD patients who achieve undetectable levels of β -hCG are at risk of perforation, infection, and higher uterine bleeding. In this case, MTX chemotherapy is the management for reducing β -hCG levels to prevent uterine rupture. Initially, the myometrial thickness was found to be 0.24 cm. After the first MTX chemotherapy cycle, the uterine cavity mass decreased, leading to an increase in myometrial thickness to 0.86 cm. The administration of MTX aims to decrease β -hCG levels, which successfully prevented uterine rupture in this GTD patient. The patient continued MTX chemotherapy until reaching the target β -hCG level and then proceeded with three cycles of consolidation therapy to prevent recurrence.

References

1. Winter MC. Treatment of low-risk gestational trophoblastic neoplasia. *Best Pract Res Clin Obstet Gynaecol*. 2021;74:67–80. doi:10.1016/j.bpobgyn.2021.01.006
2. Lok C, van Trommel N, Massuger L, Golfier F, Seckl M. Clinical Working Party of the E. Practical clinical guidelines of the EOTTD for treatment and referral of gestational trophoblastic disease. *Eur J Cancer* 2020;130:228e40.
3. Parker VL, Pacey AA, Palmer JE, Tidy JA, Winter MC, Hancock BW. Classification systems in Gestational trophoblastic neoplasia - sentiment or evidenced based? *Cancer Treat Rev* 2017;56:47e57.
4. Bagshawe KD. Risk and prognostic factors in trophoblastic neoplasia. *Cancer* 1976;38(3):1373e85.
5. Kohorn EI, Goldstein DP, Hancock BW, Kim SJ, Lurain JR, Newlands E, et al. Workshop report: combining the staging system of the international federation of Gynecology and Obstetrics with the scoring system of the world health organization for trophoblastic neoplasia. Report of the working committee of the international society for the study of trophoblastic disease and the international gynecologic cancer society. *Int J Gynecol Cancer* 2000;10(1):84e8.
6. Ngan HY, Bender H, Benedet JL, Jones H, Montruccoli GC, Pecorelli S, et al. Gestational trophoblastic neoplasia, FIGO 2000 staging and classification. *Int J Gynaecol Obstet* 2003;83(Suppl 1):175e7.
7. Ngan HY. The practicability of FIGO 2000 staging for gestational trophoblastic neoplasia. *Int J Gynecol Cancer* 2004;14(2): 202e5.
8. Osborne RJ, Filiaci V, Schink JC, Mannel RS, Alvarez Secord A, Kelley JL, et al. Phase III trial of weekly methotrexate or pulsed dactinomycin for low-risk gestational trophoblastic neoplasia: a gynecologic oncology group study. *J Clin Oncol* 2011;29(7):825e31.
9. Chapman-Davis E, Hoekstra AV, Rademaker AW, Schink JC, Lurain JR. Treatment of nonmetastatic and metastatic low-risk gestational trophoblastic neoplasia: factors associated with resistance to single-agent methotrexate chemotherapy. *Gynecol Oncol* 2012;125(3):572e5.
10. Sita-Lumsden A, Short D, Lindsay I, Sebire NJ, Adjogatse D, Seckl MJ, et al. Treatment outcomes for 618 women

- with gestational trophoblastic tumours following a molar pregnancy at the Charing Cross Hospital, 2000-2009. *Br J Cancer* 2012;107(11):1810e4.
11. Taylor F, Grew T, Everard J, Ellis L, Winter MC, Tidy J, et al. The outcome of patients with low risk gestational trophoblastic neoplasia treated with single agent intramuscular methotrexate and oral folinic acid. *Eur J Cancer* 2013;49(15):3184e90.
 12. Eysbouts YK, Ottevanger PB, Massuger L, Int'Hout J, Short D, Harvey R, et al. Can the FIGO 2000 scoring system for gestational trophoblastic neoplasia be simplified? A new retrospective analysis from a nationwide dataset. *Ann Oncol* 2017;28(8):1856e61.
 13. Uberti EM, Fajardo Mdo C, da Cunha AG, Frota SS, Braga A, Ayub AC. Treatment of low-risk gestational trophoblastic neoplasia comparing biweekly eight-day Methotrexate with folinic acid versus bolus-dose Actinomycin-D, among Brazilian women. *Rev Bras Ginecol Obstet.* 2015;37(6):258-265. doi:10.1590/SO100-720320150005366
 14. Bagshawe KD, Dent J, Newlands ES, Begent RH, Rustin GJ. The role of low-dose methotrexate and folinic acid in gestational trophoblastic tumours (GTT). *Br J Obstet Gynaecol* 1989;96(7):795e802.
 15. Chalouhi GE, Golfier F, Soignon P, Massardier J, Guastalla JP, Trillet-Lenoir V, et al. Methotrexate for 2000 FIGO low-risk gestational trophoblastic neoplasia patients: efficacy and toxicity. *Am J Obstet Gynecol* 2009;200(6):643 e1e6.
 16. Lurain JR. Gestational trophoblastic disease II: classification and management of gestational trophoblastic neoplasia. *Am J Obstet Gynecol* 2011;204(1):11e8.
 17. Ngan, H. Y. S. et al. (2021) 'Diagnosis and management of gestational trophoblastic disease: 2021 update', *International Journal of Gynecology and Obstetrics*, 155(S1), pp. 86–93. doi: 10.1002/ijgo.13877
 18. Ronnett, B. M. (2019) 'Hydatidiform moles: differential diagnosis, diagnostic reproducibility, genetics and ancillary techniques to refine diagnosis', *Diagnostic Histopathology*. doi: 10.1016/j.mpdhp.2018.12.003
 19. Kusuma, A. I. and Pramono, B. A. (2017) 'Karakteristik Mola Hidatidosa Di Rsup Dr. Kariadi Semarang', *Jurnal Kedokteran Diponegoro*, 6(2), pp. 319–327. Available at: <http://ejournal-s1.undip.ac.id/index.php/medico>
 20. Biscaro, A., Braga, A. and Berkowitz, R. S. (2015) 'Diagnosis, classification and treatment of gestational trophoblastic neoplasia', *Rev Bras Ginecol Obstet.*, 37(1), pp. 42–51. doi: 10.1590/SO100-720320140005198
 21. Petrilli ES, Twiggs LB, Blessing JA, Teng NH, Curry S. Single-dose actinomycin-D treatment for nonmetastatic gestational trophoblastic disease. A prospective phase II trial of the Gynecologic Oncology Group. *Cancer* 1987;60(9):2173e6
 22. Schlaerth JB, Morrow CP, Nalick RH, Gaddis Jr O. Single-dose actinomycin D in the treatment of postmolar trophoblastic disease. *Gynecol Oncol* 1984;19(1):53e6.
 23. Li L, Wan X, Feng F, Ren T, Yang J, Zhao J, et al. Pulse actinomycin D as first-line treatment of low-risk postmolar nonchoriocarcinoma gestational trophoblastic neoplasia. *BMC Cancer* 2018;18(1):585.
 24. Muhammad S. Invasive Mole With Impending Uterine Rupture: A Case Report. *J Midwifery*. 2022;7(2)
 25. Wu A, Zhu Q, Tan C, Chen L, Tao Y. Invasive Mole Resulting in Uterine Rupture: A Case Report. *Front Surg*. 2022;8:798640. Published 2022 Jan 28. doi:10.3389/fsurg.2021.798640
 26. Berek JS, Novak E. Berek and Novak's

- Gynecology. 7th ed. Philadelphia, PA:
Lippincott Williams & Wilkins; 2004
27. Winter MC. Treatment of low-risk
gestational trophoblastic neoplasia. Best
Pract Res Clin Obstet Gynaecol.
2021;74:67-80. doi:10.1016/j.
bpobgyn.2021.01.006